

# Immobilized Chicks as a Model System for Early-Onset Developmental Dysplasia of the Hip

Niamh C. Nowlan,<sup>1,2</sup> Vikesh Chandaria,<sup>2</sup> James Sharpe<sup>1,3</sup>

<sup>1</sup>EMBL-CRG Systems Biology Program, Centre for Genomic Regulation, UPF, Dr. Aiguader 88 08003, Barcelona, Spain, <sup>2</sup>Department of Bioengineering, Imperial College London, London, United Kingdom, <sup>3</sup>Institució Catalana de Recerca i Estudis Avançats (ICREA), Barcelona, Spain

Received 23 May 2013; accepted 3 February 2014

Published online 3 March 2014 in Wiley Online Library (wileyonlinelibrary.com). DOI 10.1002/jor.22606

**ABSTRACT:** We have almost no understanding of how our joints take on their range of distinctive shapes, despite the clinical relevance of joint morphogenesis to postnatal skeletal malformations such as developmental dysplasia of the hip (DDH). In this study, we investigate the role of spontaneous prenatal movements in joint morphogenesis using pharmacological immobilization of developing chicks, and assess the system as a suitable model for early-onset hip dysplasia. We show that, prior to joint cavitation, the lack of dynamic muscle contractions has little impact on the shape of the hip joint. However, after the timepoint at which cavitation occurs, a dramatic effect on hip joint morphogenesis was observed. Effects in the immobilized chicks included flattening of the proximal femur, abnormal orientation of the pelvis relative to the femur and abnormal placement and coverage of the acetabulum. Although many clinical case studies have identified reduced or restricted movement as a risk factor for DDH, this study provides the first experimental evidence of the role of prenatal movements in early hip joint development. We propose that the immobilized chick embryo serves as a suitable model system for the type of early-onset DDH which arises due to neuromuscular conditions such as spinal muscular atrophy. © 2014 Orthopaedic Research Society. Published by Wiley Periodicals, Inc. *J Orthop Res* 32:777–785, 2014.

**Keywords:** skeletal development; joint morphogenesis; joint shape; biomechanics; chick immobilization

Joint morphogenesis, the emergence of shape, has been referred to as the “least understood aspect of joint formation,”<sup>1</sup> and we have very little understanding of the mechanisms directing the development of joint shape, despite the clinical significance of this process. The most commonly presenting condition resulting from abnormal fetal joint morphogenesis is developmental dysplasia of the hip (DDH). DDH is a condition in which hip joint morphogenesis does not proceed correctly, and occurs when the juvenile hip joint is unstable, partially dislocated (subluxated), or completely dislocated.<sup>2</sup> The condition has an incidence of 5 per 1,000 hips<sup>3</sup> and if treatment is not administered or is unsuccessful, osteoarthritis is likely to develop. There are several important deficiencies in our basic understanding of DDH. Because DDH is more common in female infants, and also has a familial trend in incidence, genetics has been assumed to play a role in DDH. Apart from identification of one gene associated with DDH incidence in a specific ethnic group (HOXD9),<sup>4</sup> no genetic risk factors for DDH have been identified in multiple populations, despite ongoing research on the topic.<sup>5</sup> While it is known that reduced or restricted movements in utero due to conditions such as neuromuscular disorders, breech position and oligohydramnios increase the risk of DDH,<sup>6</sup> the hypothesis that reduced movement in the womb can lead to DDH has never been tested experimentally, and there is no animal model system

for pre or neo-natal onset DDH. The closest model system to human DDH is canine hip dysplasia (CDH), a common hip condition in dogs. However, CDH is never present at birth,<sup>7</sup> while most human infants diagnosed with DDH will have indications of the condition at, or soon after, birth.

Two main types of dislocation have been identified; teratologic dislocations and typical dislocations.<sup>2</sup> Teratologic dislocations occur early in utero and are associated with abnormal muscle activity, for example, in the case of neuromuscular disorders.<sup>2</sup> Early-onset forms of DDH have also been referred to as “paralytic” DDH.<sup>6</sup> Typical dislocations occur in otherwise healthy infants, and occur later in development or after birth. In the final stages of gestation, environmental factors such as breech and oligohydramnios increase the risk of DDH,<sup>2</sup> and straight leg swaddling increases the risk of DDH developing after birth.<sup>2</sup> A recent study from Wang and colleagues demonstrated that straight-leg swaddling after birth, particularly early or prolonged swaddling, increased the risk of postnatal onset hip dysplasia in a rat animal model system.<sup>8</sup>

The most important events of very early hip joint development are the formation and morphogenesis of the proximal femur and pelvic bones, and the encapsulation of the femoral head by the acetabulum. Development of the human hind limb was described in detail as early as 1901 by Bardeen and Lewis<sup>9</sup> and in more detail by Bardeen in 1905.<sup>10</sup> As described by Bardeen,<sup>10</sup> at 11 mm crown to rump length (around 7 weeks gestational age; conversion from crown to rump length to gestational age from Hadlock et al.<sup>11</sup>), the femur and pelvic blastemas are present and undergoing chondrification. At this stage of development, the femoral blastema is still continuous with pelvis. By 14 mm (around 7.5 weeks), the three rudiments of the pelvis are distinct, while a simple femoral head with

Conflict of interest: None.

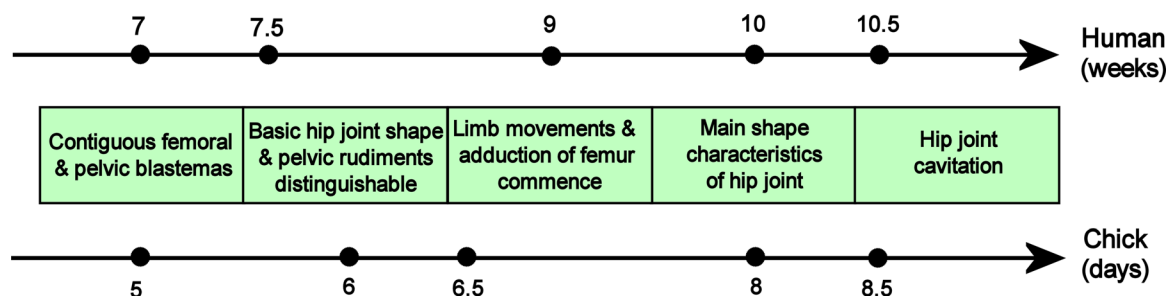
Grant sponsor: Intra-European Fellowship (IEF), Marie Curie Actions under the European Commission Seventh Framework Programme.

Correspondence to: Niamh C. Nowlan (T: +44-20-759-451-89; F: +44-20-759-49817; E-mail: n.nowlan@imperial.ac.uk)

© 2014 Orthopaedic Research Society. Published by Wiley Periodicals, Inc.

the beginnings of a greater trochanter is present. At this stage, the femur has a “dumbbell” shape, is at an angle of 45° to the sagittal midplane of the embryo, and is almost perpendicular to the developing pelvis.<sup>12</sup> The first fetal movements occur at around 7 weeks, while independent limb movements have been reported from 9 gestational weeks.<sup>13</sup> From 23 mm (9 weeks), the femur becomes increasingly adducted, with an angle of 20° to the midline apparent by 30 mm (almost 10 weeks).<sup>12</sup> By 20 mm (8.5 weeks) the acetabulum is formed by the fusion of the three pelvic rudiments, and a short femoral neck is evident. By 33 mm (10 weeks), the main shape characteristics of the pelvis and proximal femur have been established.<sup>10</sup> Coverage of the developing femoral head is shallow at the initial formation of the acetabulum, but by the time the joint cavity appears between 36 and 42 mm (10–11 weeks), much of the femoral head is enclosed by the acetabulum.<sup>12</sup> The acetabulum becomes progressively more shallow up until soon after birth.<sup>14</sup> The femoral head also changes shape during the fetal period. The femoral head is almost globular during early development, but approaches a hemi-spherical shape at birth.<sup>14</sup> During postnatal growth, the femoral head once again becomes more globular, but never becomes as spherical as it was during early development.<sup>14</sup> The key aspects of hip joint development have also been described for the chick in a recent study from our group.<sup>15</sup> At Hamburger Hamilton<sup>16</sup> (HH) stage 26 (day 5 of incubation), the pelvic and femoral blastema are present and continuous at the hip joint.<sup>15</sup> The ilium and ischium are identifiable at HH27, while the pubis is present by HH28 (6 days of incubation).<sup>15</sup> Independent limb movements first occur at 6.5 days (HH29),<sup>17</sup> prior to the formation of the perforated acetabulum by HH31. The major anatomical features of the femoral head are present at HH32 (day 8), a day prior to cavitation of the hip joint at HH34 (day 8.5). Similarly to that of the human embryo, the developing chick femur undergoes gradual rotation with respect to the pelvis and body axis with increased adduction between HH29 and HH35.<sup>15</sup> The key events in hip development follow the same sequence in both the human and chick embryo/fetus, as illustrated for both timelines in Figure 1.

Immobilization of developing chicks has been extensively used to characterize the effects of prenatal movements on skeletal development [reviewed in<sup>18</sup>]. Rigid paralysis (normally induced using neuromuscular blocking agent decamethonium bromide<sup>19</sup>) and flaccid paralysis (e.g., with pancuronium bromide<sup>20</sup>) lead to similar effects on the skeleton, but flaccid paralysis has been shown to have more severe effects on joint development.<sup>20</sup> The major effects of immobilization on skeletal development include abnormal curvature of the mandible, neck and spine, decreased growth and ossification rates in all rudiments, with some rudiments more severely affected than others.<sup>21</sup> Sesamoid formation and meniscus development are also abnormal in immobilized embryos.<sup>22,23</sup> Immobilization has been shown to have no effect on joint site specification,<sup>22,24,25</sup> but a large body of evidence has demonstrated that joint cavitation does not occur in any major synovial joint in immobilized embryos.<sup>19,20,22,26,27</sup> Only a very small number of studies have focused on the effects of an abnormal mechanical environment on joint shape morphogenesis. Roddy et al.<sup>28</sup> studied shape changes in the knee joint of chicks immobilized for up to 5 days, and found that immobilization had the effect of simplifying the joint shape, with flattened articular surfaces of the condyles, loss of functional outgrowths such as the region of the trochlea fibularis and a reduction in the width of the intercondylar fossa.<sup>28</sup> The expression patterns of a number of genes involved in regulation of cartilage growth (PTHLP, FGF2, and BMP2) were altered in the immobilized specimens,<sup>28</sup> implicating these genes in the mechanoregulation of shape morphogenesis. Mikic et al.<sup>25</sup> investigated patterns of extracellular matrix proteins during joint formation, and identified altered production of Tenascin C in the chondroepiphyses of immobilized embryos as a possible contributor to morphological abnormalities due to immobilization. Drachman and Sokoloff<sup>22</sup> also reported flattening of the articular surfaces, while Osborne et al.<sup>20</sup> found a marked decrease in the width of the cartilage epiphyses due to in ovo immobilization. Wong et al.<sup>29</sup> immobilized chick embryos by surgically excising the lumbosacral portion of the neural tube, and found that the immobilized joints had smaller chondro-



**Figure 1.** Key events during early hip development, with timelines for human and chick development. Source references contained within text.

phiphyses with irregular and flattened surfaces with greater flaring. While abnormal morphogenesis of the elbow joint has been reported for mouse knockouts which develop without any skeletal muscle,<sup>30,31</sup> no detailed studies of joint morphogenesis have been performed in the “muscleless limb” mutant mice. To the best of our knowledge, nothing has been reported on hip joint morphogenesis in any model system of abnormal prenatal movements.

There is a pressing need to understand how prenatal movements affect joint shape, and a need to investigate if animal models of abnormal prenatal movement could serve as a suitable experimental model for DDH. In this study, we investigate the effects of blocking spontaneous movements using a neuromuscular blocking agent from day 4 of incubation on hip joint morphogenesis at days 7, 8, and 9, spanning a rapid period of morphogenesis both before and after joint cavitation. The first movements in the chick occur at 3.5 days of incubation (HH21),<sup>17</sup> while independent movements of the limb first occur at 6.5 days (HH29),<sup>17</sup> and therefore commencing immobilization treatments at day 4 ensures that no limb movements should occur in the experimental embryos. We use Optical Projection Tomography (OPT)<sup>32</sup> in order to obtain 3-D images of the hip joint shape under normal and immobilized conditions in ovo. Direct 3D capture enables shape analysis of the hip joint from a range of angles, using virtual sections, and does not incur distortions associated with physical sectioning or histological methods. This study provides an experimental test of the hypothesis that restricted or abnormal movements in the womb increases the risk of abnormal hip development. If features of DDH are found in the immobilized chick embryos, this will provide the first model system for prenatal onset DDH.

## METHODS

Fertilized eggs, supplied by a local farm (Granja Gilbert, Cataluña, Spain) were incubated at 38°C in a humidified incubator for 7–9 days. Following 3 days of incubation, 3 ml of albumin was removed from the eggs. At day 4 of incubation, the immobilization treatment was started. Control embryos were treated daily with 100 µl of PBS plus 100 units/ml antibiotic/antimycotic (Pen. Strep., Gibco, Fisher Scientific, Madrid, Spain), while immobilized embryos were treated daily with 100 µl of 0.5% Decamethonium Bromide (DMB, Sigma) in PBS, also with 100 units/ml antibiotic/antimycotic. Decamethonium bromide is a neuromuscular blocking agent which induces rigid paralysis, where contraction of all skeletal muscle fibers is sustained.<sup>20</sup> Sustained immobilization has been shown to decrease the length, mass, and cross-sectional area of muscles, and the isometric contractile properties were also found to be affected in the muscles of immobilized embryos.<sup>33</sup> The experiments were performed in accordance with European Legislation (Directive 86/609/EEC), under which no license is necessary when working with embryos younger than two thirds through gestation. Immobilized embryos were monitored for movement daily, and no independent spontaneous limb movements were detected during monitoring. Twenty-eight

control and 32 experimental embryos were harvested on days 7, 8, and 9 of incubation, as detailed in Table 1, and all embryos were staged using the Hamburger Hamilton (HH)<sup>16</sup> staging system. The right limb of each embryo was sectioned through the anterior-posterior plane of the femur and stained as described previously<sup>34</sup> with Weigert's Iron Hematoxylin, Fast Green and Safranin-O. The left limb of each embryo was stained for cartilage with Alcian Blue and scanned in 3D using Optical Projection Tomography (OPT)<sup>32</sup> as described previously.<sup>35</sup> Surface representations of the limbs were created using ImageJ (<http://rsbweb.nih.gov/ij/>, last accessed December 2013).<sup>36</sup> The hip joint was visualized in a number of ways using Paraview (<http://www.paraview.org/>, last accessed December 2013),<sup>37</sup> as described previously<sup>15</sup>; with surface views of the pelvis and femur, virtual sections through the pelvis and femur, surface view of the pelvis with the femur virtually removed, and surface views of the femur with the pelvis virtually dissected. An additional virtual section through the anti-trochanter, parallel to the main axis of the femur was also analyzed. The anti-trochanter is a feature of the pelvis specific only to birds, and is an outgrowth of the ischium adjacent to the junction with the ilium which articulates with the femoral head in certain movements. Rudiments were virtually dissected out from the full image using ImageJ. Individual rudiments were visualized by color, where the boundaries between the rudiments were determined by eye, with the knowledge that the three rudiments of the pelvis together form the acetabulum.<sup>38</sup> As some limbs were damaged in the process, the final numbers analyzed were slightly lower than the harvested numbers, as detailed in Table 1 with their developmental stages. For each timepoint, specimens were compared for the standardized views described above, and at least two representative limbs from each group were selected for presentation. The size of the pre-acetabular ilium was compared between groups, and standard *t*-tests were used to compare between control and immobilized specimens at each timepoint, where a *p*-value of less than 0.05 was taken as a statistically significant difference. Since it has already been demonstrated that rudiment size is decreased in immobilized chicks [reviewed in<sup>39</sup>], the ratio of the pre-acetabular ilium to the width of the entire ilium (at its largest width) was used to calculate this difference in order to investigate whether the size of this individual part of the ilium was indeed changing due to immobilization.

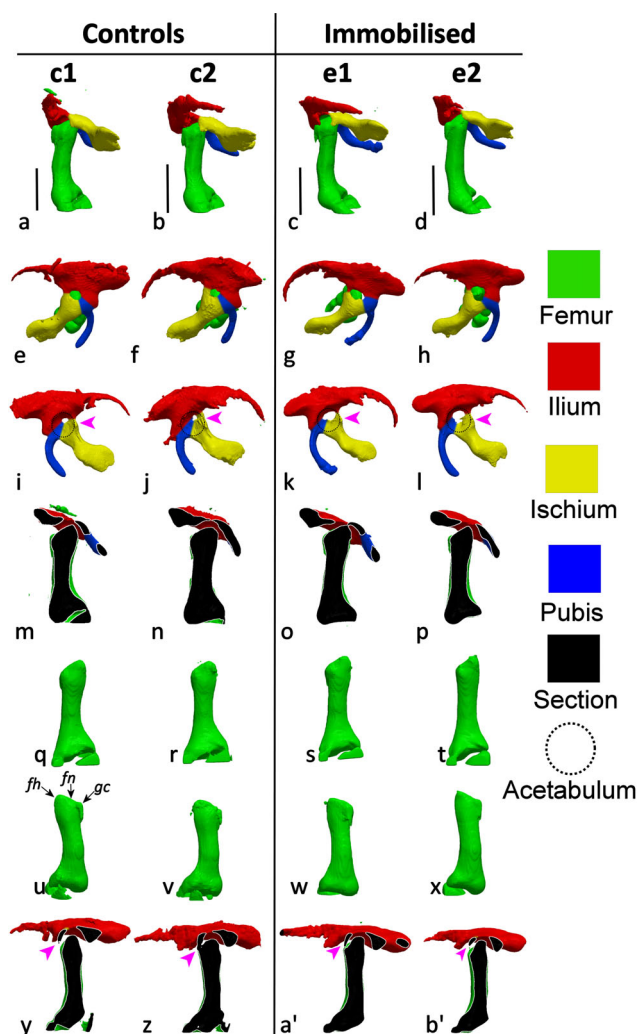
## RESULTS

At day 7, after 3 days of treatment, there was no apparent effect of immobilization on any aspect of hip

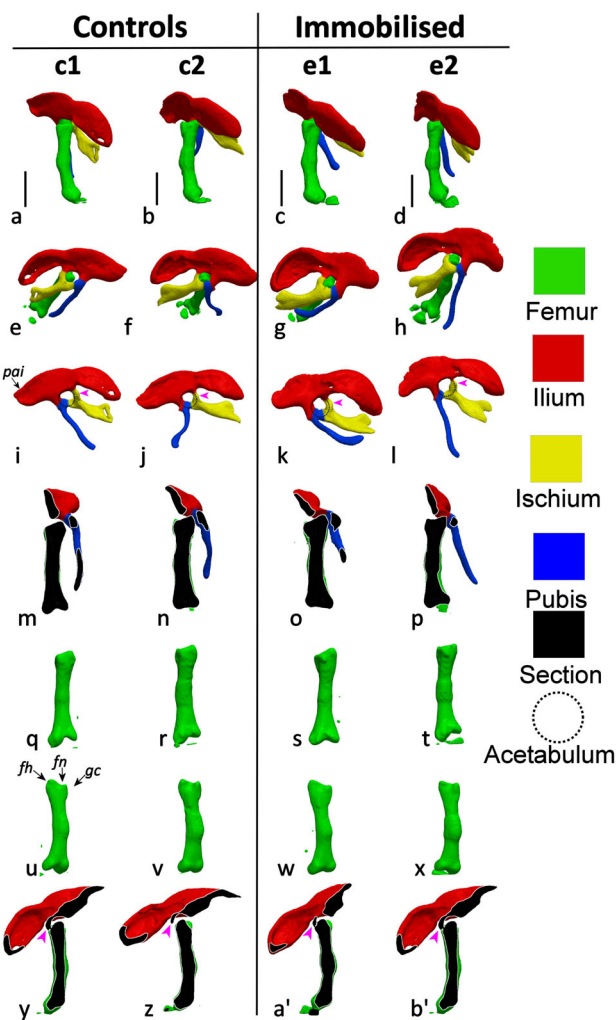
**Table 1.** Numbers of Embryos Harvested and Analyzed Per Day for Control and Immobilized Groups, With the Hamburger Hamilton (HH) Stages of Analyzed Limbs

	Harvested: Controls	Harvested: Immobilized	Fully Analyzed: Controls	Fully Analyzed: Immobilized
Day 7	8	9	7: HH30	7: HH30
Day 8	10	11	3: HH31 6: HH32	3: HH31 6: HH32
Day 9	10	12	2: HH34 7: HH35	2: HH34 7: HH35

or pelvic development. Proximal femora from both groups showed indications of the femoral head and neck and the greater trochanter, while there were no differences between the control and immobilized groups for the shape or orientation of the pelvic rudiments, as shown in Figure 2. At day 8, after 4 days of treatment, there were no differences in morphology of the proximal femur, in the orientation of the femur or the pelvic rudiments, or in the position of the acetabulum, as shown in Figure 3. The only effect detected at day 8 was a change in the size of the pre-acetabular ilium (as labeled in Fig. 3) relative to the width of the entire ilium, which was significantly lower in the immobilized limbs ( $p < 0.05$ ) (Fig. 3e–l).<sup>40</sup> Some specimens had particularly delicate pubic bones



**Figure 2.** Pelvic and femoral development at day 7 for control (left) and experimentally immobilized (right) chick embryos. (a–d) Pelvis and femur, ventral aspect of femur, (e–h) pelvis and femur ventral aspect of pelvis, (i–l) dorsal aspect of pelvis, (m–p) virtual section through the femoral head and parallel to the main axis of the femur, (q–t) posterior aspect of femur, (u–x) anterior aspect of femur, fh, femoral head; fm, femoral neck; gc, greater trochanter; (y–b') virtual section through the anti-trochanter, parallel to the main axis of the femur. Magenta arrowheads refer to the anti-trochanter. Scale bars 1 mm.

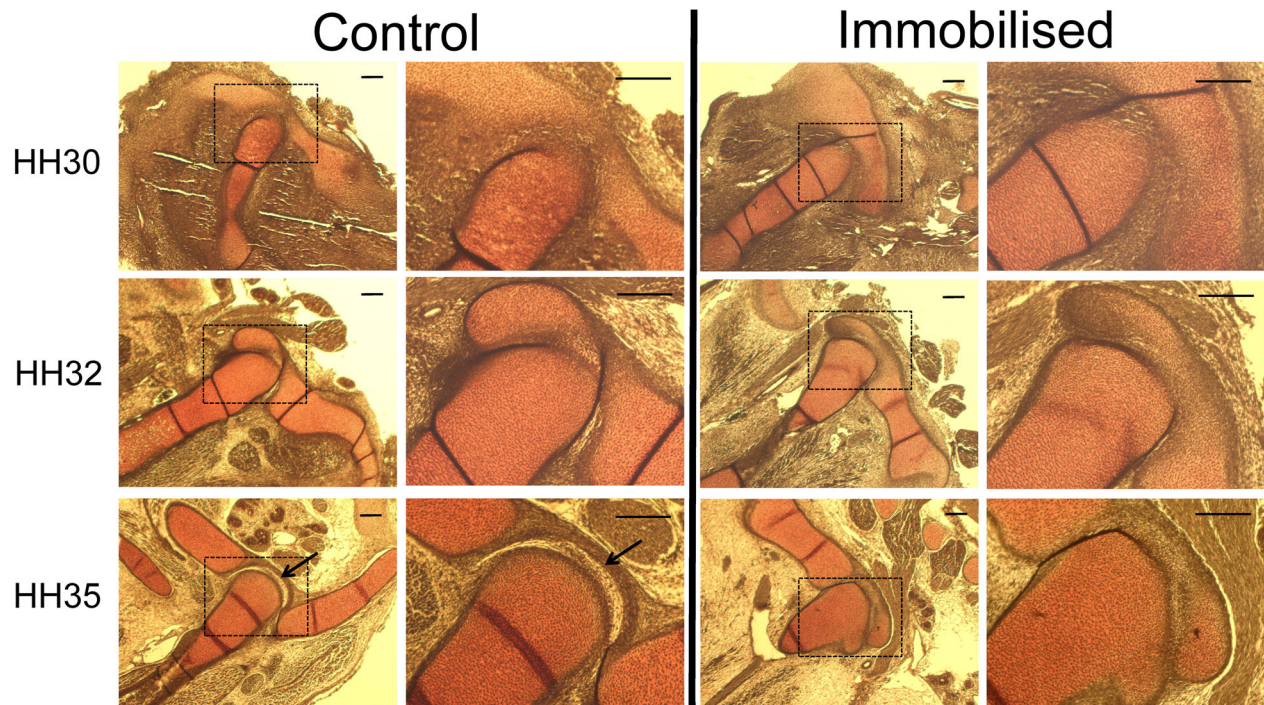


**Figure 3.** Pelvic and femoral development at day 8 for control (left) and experimentally immobilized (right) chick embryos. (a–d) Pelvis and femur, ventral aspect of femur, (e–h) pelvis and femur ventral aspect of pelvis, (i–l) dorsal aspect of pelvis (abnormal orientation of pubis in [i, j and l] is due to damage during processing), (m–p) virtual section through the femoral head and parallel to the main axis of the femur, (q–t) posterior aspect of femur, (u–x) anterior aspect of femur, fh, femoral head; fm, femoral neck; gc, greater trochanter; (y–b') virtual section through the anti-trochanter, parallel to the main axis of the femur. Magenta arrowheads refer to the anti-trochanter. Scale bars 1 mm.

whose orientation was altered in the clearing stage after staining, as shown in Figure 3j and l. The pubis is normally adjacent to the ischium, as shown in Figure 3k. As this artefact occurred in a number of both control and immobilized specimens, the size or alignment of the pubis has not been analyzed in this study. No differences were apparent in histological sections of control and immobilized limbs at day 7 or 8, when no cavity was yet present in either group, as shown in Figure 4.

In contrast to specimens harvested at day 7 and 8, almost all features of the hip joint were affected in the immobilized limbs harvested at day 9. Of the nine limbs analyzed in detail, eight of them had an abnormal shape or protuberance of the femoral head, as





**Figure 4.** Histological sections of the right hip joint through the anterior-posterior plane of the femur for each timepoint. Cavitation of the hip joint has occurred by day 9 in the controls but not in the immobilized specimens. Scale bars 200  $\mu$ m.

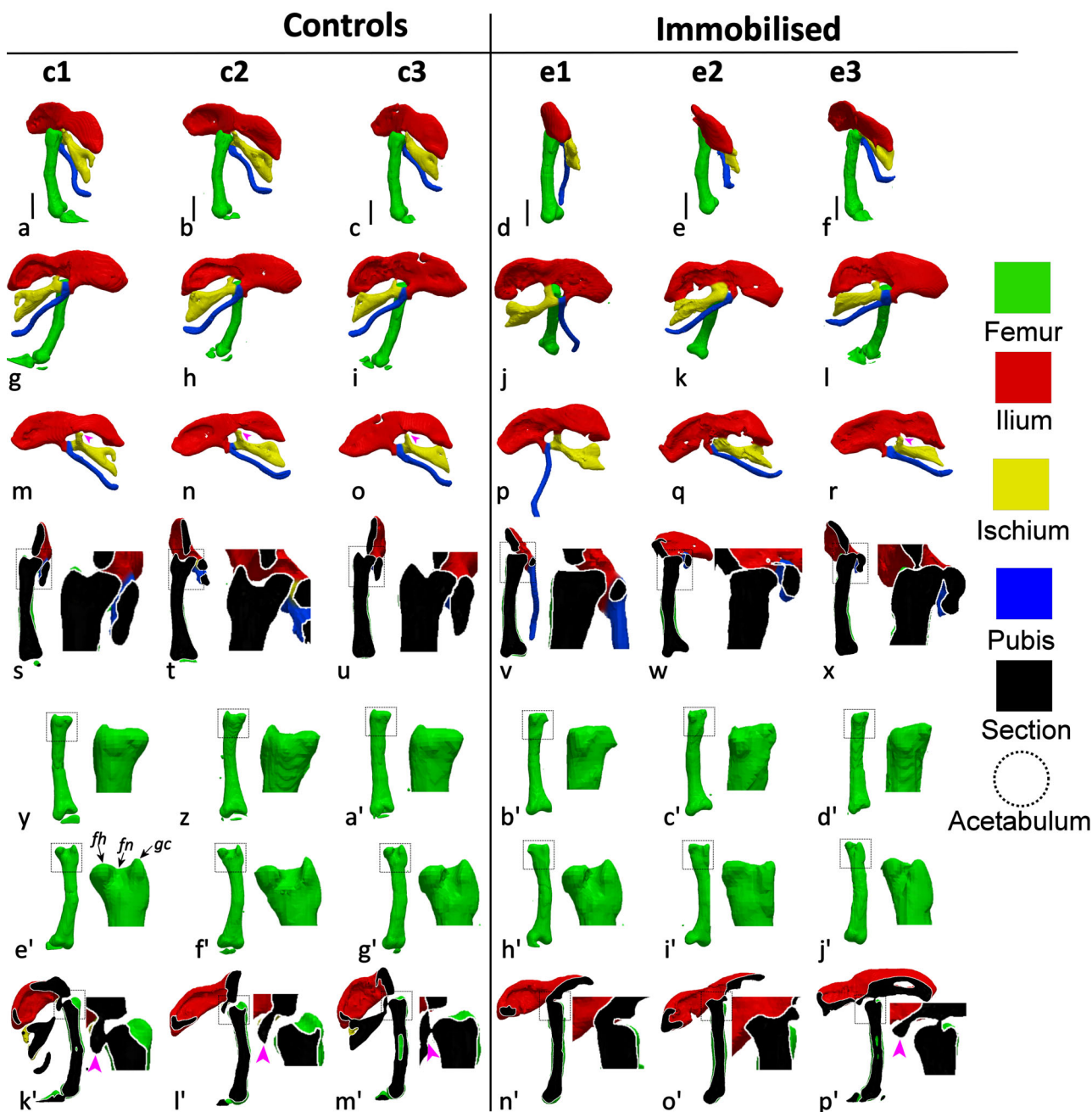
shown in Figure 5 (rightmost 3 columns). Seven out of 9 of the immobilized limbs had abnormal or absent indentation of the femoral neck relative to the femoral head and greater trochanter as compared to control limbs as shown in Figure 5 (rightmost 3 columns). None of the immobilized hip joints at day 9 had both a normal femoral neck and femoral head. There were other abnormalities seen in the day 9 limbs, such as the orientation of the pelvis relative to the femur, which was different between the control and immobilized groups; compare Figure 5s–u, a–c with v–x, d–f. In the control group at day 9, sections through the ilium at the femoral head show that the ilium is almost parallel to the femur as shown in Figure 5s–u. However, in the immobilized group, the orientation of the equivalent section of the ilium relative to the femur was the same as in specimens from the previous day (compare Fig. 5v–x with Fig. 3m–p). The relationship between the pelvis and femur was also abnormal in other ways, such as the positioning of the acetabulum. In a section through the femoral head, the distal ilium is normally positioned in the indented femoral neck (Fig. 5s–u). However, in some immobilized limbs, as shown in Figure 5w, the ilium is positioned at the femoral head, away from the location at which the indentation of the femoral neck should be. In some specimens, in a virtual section through the anti-trochanter, it was not possible to separate the ilium (at the anti-trochanter) from the proximal femur in some immobilized specimens due to fusion of the rudiments at the joint, as shown in Figure 5n' and o'. As in the day 8 specimens, the orientation of some

pubic bones (Fig. 5o, p) were affected by the staining process, and no analyses were performed on this rudiment. When the length of the pre-acetabular ilium relative to the width of the entire ilium was measured, there was no significant difference between the control and immobilized groups at day 9 for this ratio. A joint cavity was present in the control embryos at day 9, but no cavities were detected in the immobilized embryos at the same timepoint, as shown in Figure 4.

Not all limbs within the immobilized group at day 9 were affected to the same degree, which is expected due to at least two sources of experimental variation; slightly different dilutions of the drug due to different sizes of eggs, and natural variations in the embryos themselves. For example, some limbs were particularly severely affected, such as the limb labeled “e2” at day 9. This limb had multiple abnormal features, such as abnormal femoral head and neck, abnormal positioning of the acetabulum and orientation of the pelvis relative to the femur, and complete fusion of the proximal femur and the pelvis in some locations (Fig. 5, 2nd column from right), while others maintained features of the normal hip joint, such as positioning of the acetabulum (e1, e3, Figure 5v, x) and anti-trochanter (e3, Figure 5p').

## DISCUSSION

In this paper, we describe how pharmacological immobilization affects shape morphogenesis of the developing chick hip joint over the period between 7 and 9 days of incubation. We have shown that immobilization had no



**Figure 5.** Pelvic and femoral development at day 9 for control (left) and experimentally immobilized (right) chick embryos. (a–f) Pelvis and femur, ventral aspect of femur, (g–l) pelvis and femur ventral aspect of pelvis, (m–r) dorsal aspect of pelvis (abnormal orientation of pubis in [o, p] is due to damage during processing), (s–x) virtual section through the femoral head and parallel to the main axis of the femur, (y–d') posterior aspect of femur, (e'–j') anterior aspect of femur. fh, femoral head; fm, femoral neck; gc, greater trochanter; (k'–p') virtual section through the anti-trochanter, parallel to the main axis of the femur. Scale bars 1 mm. Magenta arrowheads refer to the anti-trochanter. Zoomed in segments (s–p') magnified 2.5 times with respect to original.

effect on any aspect of hip joint shape on day 7 of incubation, with immobilization applied from day 4. At day 8 of incubation, the only effect of immobilization found was in the pelvic anatomy, as the length of the pre-acetabular portion of the ilium was decreased as compared to the total length of the ilium. However, at day 9 of incubation, a range of effects on joint shape were seen in the immobilized chicks, with specimens exhibiting abnormal shaping of the proximal femoral

head and acetabulum, and abnormal positioning and orientation of the pelvis with respect to the femoral head. Therefore, the hypothesis that restricted or abnormal fetal movements lead to abnormal hip joint development has been corroborated by our results. The abnormalities found in the immobilized chicks are features of severe DDH, and we propose that the immobilized chick embryo model system is a suitable animal model for early-onset DDH.

The first two groups of control and immobilized limbs analyzed (harvested on days 7 and 8), which were staged between HH30 and HH33, had not yet undergone cavitation (Fig. 4). Our results show that, apart from a decrease in the length of the pre-acetabular portion of the ilium, no effect on hip joint shape was detected due to immobilization in the pre-cavitation joints. However, by day 9 of incubation, when the chicks were staged between HH34 and HH35, cavitation has occurred in the controls, but not in the immobilized embryos, as shown in Figure 4. This finding concurs with numerous studies which have reported failure of cavitation in immobilized chick limbs.<sup>19,20,22,26,27</sup> Differences in shape were also detectable in histological sections, where in the day 9 immobilized specimens the shape of the femoral head was similar to the shape at day 8, while in the control specimens at day 9 the shape has become much more defined. Dramatic effects on almost all aspects of the hip joint were evident from the 3D scans at day 9 of incubation; the pelvis does not undergo normal changes in orientation, the shape of the femoral head is simpler in shape than controls at the same age, and the size and positioning of the perforated acetabulum is also affected. Our results suggest that cavitation is crucial to the development of the complex shape of the proximal femur and to the correct orientation and interaction between the acetabulum and pelvis and the proximal femur.

These results raise some key issues relating to the sequence of events in the developing joint, which is illustrated in Figure 1 for human and chick development. Previous work from our group demonstrated that the major morphological features of the hip joint are present at least 1.5 days prior to cavitation,<sup>15</sup> and we previously hypothesized that pre-cavitalional movements at the joint could influence early morphogenesis. However, this hypothesis has been rejected by our current work, as despite the fact that pre-cavitalional movements at the hip joint were absent in the immobilized embryos, shape morphogenesis of the hip proceeded as normal in the immobilized hips at days 7 and 8. Therefore, we can conclude that pre-cavitalional flexion of the joints does not play a role in early joint shape morphogenesis. Growth related strains<sup>41</sup> could potentially still play a role, or alternatively, the process of early joint shape morphogenesis could be entirely biologically determined. Pre-cavitalional movements have long been identified as promoting cavitation through physical separation of the rudiments,<sup>22,42</sup> and this has been borne out in our results, with no cavitation occurring in the day 9 immobilized embryos. In contrast to the lack of influence of pre-cavitalional movements on joint shape, the current research shows that physical separation by cavitation and/or post-cavitalional movements are essential for the refinement and modulation of joint shape. While others have shown effects of immobilization on the shape of the pre-cavitalional knee (stifle),<sup>20,25,28</sup> an-

kle<sup>20,29</sup> and interphalangeal joint,<sup>20,25</sup> ours is the first study to show that morphogenesis proceeds as normal in the absence of limb movements up until the point at which cavitation should occur. We propose that while early stage morphogenesis does not depend on limb movements, late stage morphogenesis is dependent on cavitation and/or local joint movements made possible by cavitation. These findings have important consequences for developing future treatments for early-onset DDH, as they show that the event of cavitation is critical to joint shape development and that, therefore, inducing cavitation when it did not occur naturally could ameliorate the effects on the hip joint.

The immobilized chick serves as a model system for so-called teratologic hip dislocations, which occur early in utero and are associated with neuromuscular problems such as spinal muscular atrophy.<sup>2</sup> While DDH incidence is greater in female infants<sup>2</sup> and in the left hip (reportedly due to restricted movement of that side because of restricted adduction next to the mother's spine),<sup>6</sup> many neuromuscular conditions are more common in male infants (e.g., X-linked spinal muscular atrophy occurs only in males), and therefore the gender and side differences that occur are likely to apply to typical DDH alone. Our results have shown that hip joint morphogenesis is dramatically affected by immobilization, but only after the point in development after which cavitation should have occurred.<sup>6</sup> The pharmacological immobilization treatment we have used is representative of only the most severe cases of neuromuscular disorders, where spontaneous movements are completely absent. However, we have identified the most severe effects of early-onset DDH, and our next steps will be to investigate if the joint can "recover" from short or intermittent periods of absent movement, to test the effects of later starting timepoints for the immobilization treatment (e.g., starting treatment at day 7 or 8) and to examine later stage immobilizations that would be representative of the more common nonsyndromic, or "typical"<sup>2</sup> DDH which arises during late gestation. As with any drug treatment, there is always a concern that the drug can interact with biological processes in an unpredicted manner. However, decamethonium bromide has previously been shown not to interfere with cartilage synthesis,<sup>43</sup> and so we are confident that the effects on joint shape are related to the lack of movements rather than a direct action of the applied drug.

This research provides the first detailed morphological description of early hip joint development under an altered mechanical environment. The use of 3D OPT imaging enabled us to obtain surface views from any angle and virtual sections in any desired orientation, and to "virtually dissect" out individual parts of the anatomy in order to visualize effects from multiple angles. Although many clinical case studies have identified reduced or restricted movement as a risk factor for abnormal hip development and DDH, this study has provided the first experimental evidence of



the role of prenatal movements in early hip joint development. Our results suggest that immobility during early hip joint development affects morphogenesis of both the acetabulum and proximal femur. The congruency of the immobilized hip joints would certainly be affected due to the significantly altered morphology, leading to dysplasia and possible dislocation. Therefore, the immobilized chick hip joints are consistent with teratologic DDH, providing the first animal model system for early-onset DDH.

## ACKNOWLEDGMENTS

This research was funded by an Intra-European Fellowship (IEF) to NCN from the Marie Curie Actions under the European Commission Seventh Framework Programme. The authors are grateful to Mr. Alexis Rafols Mitjans and the CRG Histology Unit for assistance with the histological analyses.

## REFERENCES

- Pacifici M, Koyama E, Iwamoto M. 2005. Mechanisms of synovial joint and articular cartilage formation: recent advances, but many lingering mysteries. *Birth Defects Res C Embryo Today* 75:237–248.
- Homer C, Baltz R, Hickson G, et al. 2000. Clinical practice guideline: early detection of developmental dysplasia of the hip. Committee on Quality Improvement, Subcommittee on Developmental Dysplasia of the Hip. *American Academy of Pediatrics. Pediatrics* 105:896–905.
- Bialik V, Bialik GM, Blazer S, et al. 1999. Developmental dysplasia of the hip: a new approach to incidence. *Pediatrics* 103:93–99.
- Tian W, Zhao L, Suo P, et al. 2012. Association analysis between HOXD9 genes and the development of developmental dysplasia of the hip in Chinese female Han population. *BMC Musculoskelet Disord* 13:59.
- Rubini M, Cavallaro A, Calzolari E, et al. 2008. Exclusion of COL2A1 and VDR as developmental dysplasia of the hip genes. *Clin Orthop Relat Res* 466:878–883.
- Aronsson D, Goldberg M, Kling T Jr, et al. 1994. Developmental dysplasia of the hip. *Pediatrics* 94:201.
- Vanden Berg-Foels WS, Todhunter RJ, Schwager SJ, et al. 2006. Effect of early postnatal body weight on femoral head ossification onset and hip osteoarthritis in a canine model of developmental dysplasia of the hip. *Pediatr Res* 60:549–554.
- Wang E, Liu T, Li J, et al. 2012. Does swaddling influence developmental dysplasia of the hip? An experimental study of the traditional straight-leg swaddling model in neonatal rats. *J Bone Joint Surg Am* 94:1071–1077.
- Bardeen CR, Lewis WH. 1901. Development of the limbs, body-wall and back in man. *Am J Anat* 1:1–35.
- Bardeen CR. 1905. Studies of the development of the human skeleton.(A). The development of the lumbab, sacbal and coccygeal vertebwe.(B). The cubves and the pbopobionate regional lengths of the spinal column during the first thbee months of embbyonic developnment.(C). The development of the skeleton of the posterior limb. *Am J Anat* 4:265–302.
- Hadlock F, Shah Y, Kanon D, et al. 1992. Fetal crown-rump length: reevaluation of relation to menstrual age (5-18 weeks) with high-resolution real-time US. *Radiology* 182:501–505.
- Strayer LM Jr. 1943. The embryology of the human hip joint. *Yale J Biol Med* 16:13.
- de Vries JIP, Fong BF. 2006. Normal fetal motility: an overview. *Ultrasound Obstet Gynecol* 27:701–711.
- Ráliš Z, McKibbin B. 1973. Changes in shape of the human hip joint during its development and their relation to its stability. *J Bone Joint Surg Br* 55:780–785.
- Nowlan NC, Sharpe J. 2013. Joint shape morphogenesis precedes cavitation of the developing hip joint. *J Anat* doi: 10.1111/joa.12143.
- Hamburger V, Hamilton HL. 1951. A series of normal stages in the development of the chick embryo. 1951. *Dev Dyn* 195:231–272. Republished 1992.
- Hamburger V, Balaban M, Oppenheim R, et al. 1965. Periodic motility of normal and spinal chick embryos between 8 and 17 days of incubation. *J Exp Zool* 159:1–13.
- Nowlan NC, Murphy P, Prendergast PJ. 2007. Mechanobiology of embryonic limb development. *Ann N Y Acad Sci* 1101:389–411.
- Hosseini A, Hogg D. 1991. The effects of paralysis on skeletal development in the chick embryo. I. General effects. *J Anat* 177:159.
- Osborne AC, Lamb KJ, Lewthwaite JC, et al. 2002. Short-term rigid and flaccid paralyses diminish growth of embryonic chick limbs and abrogate joint cavity formation but differentially preserve pre-cavitated joints. *J Musculoskelet Neuronal Interact* 2:448.
- Hall BK, Herring S. 1990. Paralysis and growth of the musculoskeletal system in the embryonic chick. *J Morphol* 206:45–456.
- Drachman DB, Sokóloff L. 1966. The role of movement in embryonic joint formation. *Dev Biol* 14:401–420.
- Mikic B, Johnson TL, Chhabra AB, et al. 2000. Differential effects of embryonic immobilization on the development of fibrocartilaginous skeletal elements. *J Rehabil Res Dev* 37:127–134.
- Mitrovic D. 1982. Development of the articular cavity in paralyzed chick embryos and in chick embryo limb buds cultured on chorioallantoic membranes. *Acta Anat (Basel)* 113:313–324.
- Mikic B, Wong M, Chiquet M, et al. 2000. Mechanical modulation of tenascin-C and collagen-XII expression during avian synovial joint formation. *J Orthop Res* 18:406–415.
- Ruano-Gil D, Nardi-Villardaga J, Tejedo-Mateu A. 1978. Influence of extrinsic factors on the development of the articular system. *Acta Anat (Basel)* 101:36–44.
- Murray P, Drachman D. 1969. The role of movement in the development of joints and related structures: the head and neck in the chick embryo. *J Embryol Exp Morphol* 22:349.
- Roddy KA, Prendergast PJ, Murphy P. 2011. Mechanical influences on morphogenesis of the knee joint revealed through morphological, molecular and computational analysis of immobilised embryos. *PLoS ONE* 6:e17526.
- Wong M, Germiller J, Bonadio J, et al. 1993. Neuromuscular atrophy alters collagen gene expression, pattern formation, and mechanical integrity of the chick embryo long bone. *Prog Clin Biol Res* 383B:587–597.
- Kahn J, Shwartz Y, Blitz E, et al. 2009. Muscle contraction is necessary to maintain joint progenitor cell fate. *Dev Cell* 16:734–743.
- Nowlan NC, Dumas G, Tajbakhsh S, et al. 2012. Biophysical stimuli induced by passive movements compensate for lack of skeletal muscle during embryonic skeletogenesis. *Biomech Model Mechanobiol* 11:207–219.
- Sharpe J, Ahlgren U, Perry P, et al. 2002. Optical projection tomography as a tool for 3D microscopy and gene expression studies. *Science* 296:541–545.
- Reiser PJ, Stokes BT, Walters PJ. 1988. Effects of immobilization on the isometric contractile properties of embryonic avian skeletal-muscle. *Exp Neurol* 99:59–72.
- Nowlan NC, Bourdon C, Dumas G, et al. 2010. Developing bones are differentially affected by compromised skeletal muscle formation. *Bone* 46:1275–1285.



35. Nowlan NC, Murphy P, Prendergast PJ. 2008. A dynamic pattern of mechanical stimulation promotes ossification in avian embryonic long bones. *J Biomech* 41:249–258.
36. Abràmoff MD, Magalhães PJ, Ram SJ. 2004. Image processing with ImageJ. *Biophotonics Int* 11:36–42.
37. Henderson A. 2007. *Paraview guide, a parallel visualization application, 2007*. Clifton Park, NY: Kitware Inc.
38. Ponseti I. 1978. Growth and development of the acetabulum in the normal child. Anatomical, histological, and roentgenographic studies. *J Bone Joint Surg Am* 60:575.
39. Nowlan NC, Sharpe J, Roddy KA, et al. 2010. Mechanobiology of embryonic skeletal development: insights from animal models. *Birth Defects Res C Embryo Today* 90:203–213.
40. Hertel F, Campbell KE Jr, James H. 2007. The antitrochanter of birds: form and function in balance. *Auk* 124:789–805.
41. Henderson J, Carter D. 2002. Mechanical induction in limb morphogenesis: the role of growth-generated strains and pressures. *Bone* 31:645–653.
42. Ito MM, Kida MY. 2000. Morphological and biochemical re-evaluation of the process of cavitation in the rat knee joint: cellular and cell strata alterations in the interzone. *J Anat* 197:659–679.
43. Mikic B, Isenstein A, Chhabra A. 2004. Mechanical modulation of cartilage structure and function during embryogenesis in the chick. *Ann Biomed Eng* 32:18–25.